



PATIENT

Rudy Schmalbach

SPECIES

Canine

BREED

Bichon

SEX

Male Neutered

AGE

2.3.12

WEIGHT

20.69lbs

INTERPRETED BY

Maggie Machen Lamy,
DVM, DACVIM
(Cardiology)

HOSPITAL NAME

Timonium Animal
Hospital

REFERRING VET

Dr. Stephe

INVOICE

27977

DATE

12.13.22

PRESENTING CLINICAL SIGNS

History: Heart murmur initially noted in February 2022, grade 2/6. Came in for coughing on 12/2/22, murmur now grade 4-5/6. Cough resolved within a week on Lasix and Pimobendan.

-Radiographs: L atrial enlargement and mild pulmonary edema.

-Current medications: Started on 12/2/22: Furosemide 12.5mg 1 PO BID for 3 days, then 12.5mg PO SID (current dose), Pimobendan 2.5mg 1 PO BID long-term

-Sedation used: Not required to complete full diagnostic ultrasound.

-Pertinent previous ultrasound results: No previous.

-STAT: Not requested

-Imaging performed by: Andi Parkinson, BS, RDMS.

ECHOCARDIOGRAM FINDINGS

2D, m-mode, color flow and doppler imaging is available. Diffuse thickening of mitral valve leaflets with mild prolapse into the left atrial lumen. Moderate eccentric mitral regurgitation with moderate left atrial dilation. Normal MR velocity. Mild LV dilation with hyperdynamic myocardial function. The tricuspid valve appears normal with trace TR. Velocity consistent with early PAH.

Normal right atrial and ventricular diameter and morphology. The pulmonic and aortic valves are normal in morphology and mobility. No AI/PI. Normal aortic outflow velocities with laminar flow. No pericardial or pleural effusion noted. No obvious cardiac masses.

CARDIAC CHART

CANINE CARDIAC PARAMETERS	MR VMAX (m/s)	TR VMAX (m/s)	LA/AO (Boon method)	LA/AO (Heart Base; Swe)	FS (%)	EF (%)	EPSS (cm)
NORMAL PARAMETER	4.5-5.5	<2.7	1.3	<1.6	28-40	40-100	<0.6
PATIENT	5.2	2.8	NM	1.8	66	94	NM
CANINE CARDIAC PARAMETERS	HR (BPM)	AV VMAX (m/s)	PV MAX (m/s)	BODY WEIGHT (kg)	LA 2D short axis Base view (cm)	LVIDd Avg; 2D and m-mode short axis (cm)	LVIDs Avg; 2D and m-mode short axis (cm)
NORMAL PARAMETER	50-100	0.7-1.7	0.7-1.6	BELOW	BELOW	BELOW	BELOW
PATIENT	176	1.1	0.80	9.4	2.8	3.5	1.2
*Normal chamber parameters expressed as a mean value (SD)				3	1.27 (5.3)	2.46 (2.46)	1.36 (5.5)
BODY WEIGHT DEPENDENT PARAMETERS				5	1.40 (4.5)	2.74 (5.2)	1.60 (4.7)
<i>*Note: All measurements based upon multi-modal images and methods. An average value is reported.</i>				10	1.50 (3.8)	3.27 (3.5)	2.06 (3.1)
				15	1.83 (2.0)	3.71 (2.4)	2.43 (2.1)
				20	2.02 (1.9)	4.14 (2.2)	2.80 (2.0)
				25	2.18 (2.4)	4.48 (2.9)	3.10 (2.5)
				30	2.33 (3.3)	4.83 (3.9)	3.39 (3.4)
				35	2.48 (4.3)	5.17 (5.0)	3.69 (4.5)
				40	2.62 (5.2)	5.48 (6.1)	3.96 (5.4)
				50	2.88 (7.1)	6.07 (8.3)	4.46 (7.4)

Adapted from June Boon, Veterinary Echocardiography, 1998
Rishniw M and Hollis NE, J Vet Intern Med 2000; 14:429-435
Hansson et al, Vet Rad and Ultrasound 2002
Bonagura et al. Echocardiography: principles of interpretation, Vet Clin North Am 15:1177, 1995

INTERPRETATION OF THE FINDINGS & FURTHER RECOMMENDATIONS

Chronic degenerative valve disease causing moderate mitral and trace tricuspid regurgitation. Moderate left atrial enlargement indicates the risk for spontaneous congestive heart failure is currently low; however, may be elevated going forward. Early pulmonary hypertension is noted, which should be monitored going forward. No additional issues are noted.

While it is uncommon for moderate valve disease to lead to CHF, if the radiographs showed pulmonary edema and the patient responded to diuretic therapy then this would support the diagnosis and medications should be continued as suggested below. That being said, if there is any question of the diagnosis a Radiologist review of the films is highly recommended. CHF is a radiographic and clinical diagnosis, which can only be supported by echocardiography. This breed is also predisposed to primary airway disease, which can also cause a clinical cough without dyspnea.

The average survival time of canine patients with active pulmonary edema is 8-9 months on medications, however they generally are able to maintain a good quality of life for that period.

Monitor for development of a cough, labored breathing, exercise intolerance or collapse episodes. Patient will always be at risk for recurrent CHF, development of arrhythmias/LA tear, syncope and/or sudden death in the future. Serial monitoring of SRRs is recommended as the best way to screen for progression to CHF at home.

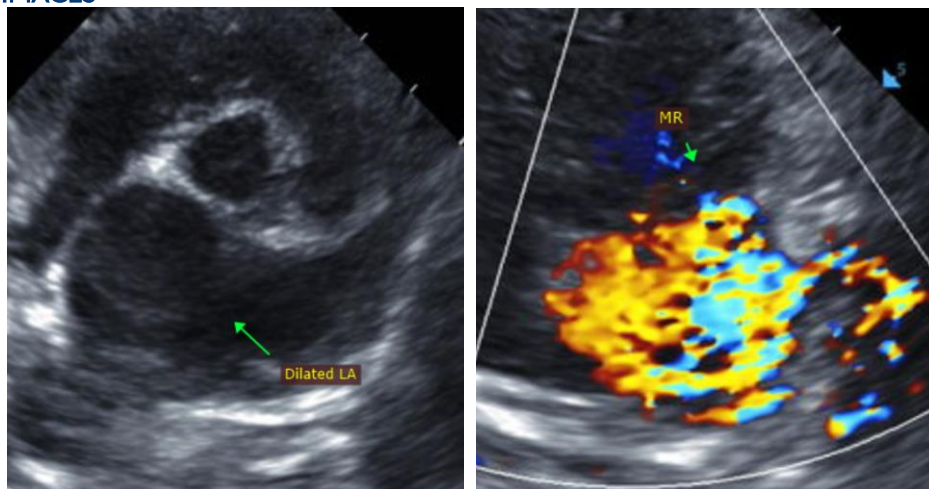
PLAN

Consider Radiologist review of the films to determine if Lasix should be continued. Recommend continue Pimobendan 0.3mg/kg PO q12h. Institute Benazepril or Enalapril 0.5mg/kg PO BID. Hydrocodone can be utilized if needed for QOL. Reassess BP as discussed.

A recheck renal panel and BP are recommended every 3-4 months lifelong.

A recheck BP and echocardiogram is recommended in 6 months to screen for progression, sooner if clinical signs arise.

IMAGES



The information and recommendations provided are based on the images presented by the referring veterinarian. No evaluation can be communicated regarding pathology that was not visible in the image/video clips provided.

Thank you for this referral. This report was generated using transcription software, and minor dictation errors may be present. If the clinical or image interpretation does not parallel your findings or if I can be of any further assistance please contact me.

Maggie Machen Lamy, DVM
Diplomate of the American College of Veterinary Internal Medicine (Cardiology)

info@sonopath.com